

# Flashes and floaters

Mr Soon Ch'ng

BMEC VR Consultant & Eye Emergency Department Lead

20<sup>th</sup> October 2020

## Financial Disclosures

No financial disclosures

Video presentation available at:

<https://youtu.be/h3tmdwtEyu4>

*This disclaimer informs readers that the views, thoughts, and opinions expressed in the text and video belong solely to the author, and not necessarily to the author's employer, organization, committee or other group or individual.*



# Flashes and Floaters



Why do people get it?




What to look out for and causes of it?



When to refer?

## Why it happens?



Vitreous synchysis

Vitreous syneresis

Posterior vitreous detachment (PVD) [other descriptive terms – Vitreo-schisis or Partial PVD]

Retinal tears

Retinal detachment

# Common causes

1. Posterior vitreous detachment → Retinal tear → Retinal detachment
2. Neurological conditions - migraine
3. Other retinal pathologies - vit haem from vein occlusions, wet AMD, DR
4. Other pathologies - uveitis, glaucoma, choroidal mass, brain tumours, papilloedema

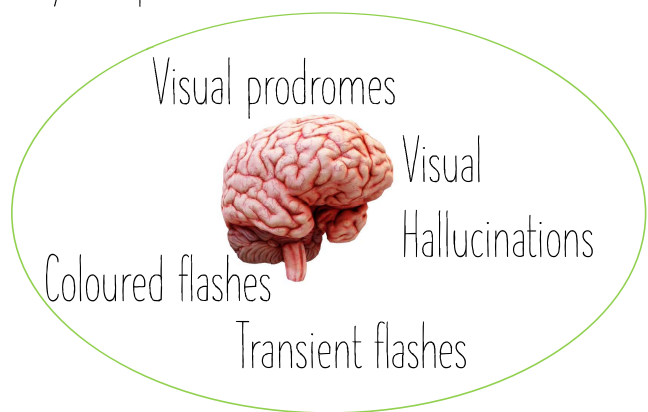
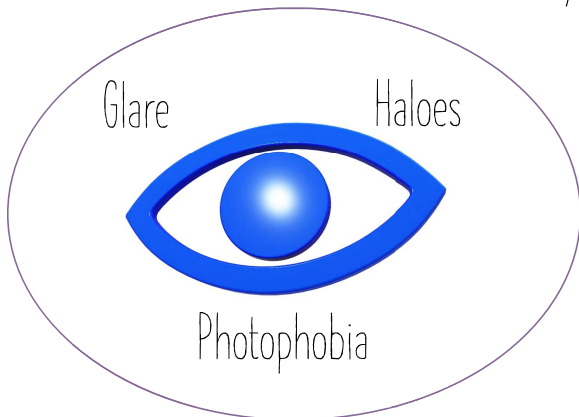
## When to refer?

Ideally - they all need a fundal examination.

A good history usually gives a clue straight away whether this is something serious.

# True flashes or pseudoflashes?

- Important to differentiate it from flashes of other causes.
- Retinal tears/detachment - flashes - typically temporal field



# Differentiating PVD, RD & others...

Characteristics	Others	PVD	RD
Age	Young (Migraine) Pseudoflashes	Middle aged	Any (young - high myopes)
Vision	Normal / Mildly blurred	Normal / Mildly blurred	Permanent disturbance
Pain	Uveitis?	Unlikely	Unlikely
Refractive Status	Any	Any	Myopic
Shadows in vision	Intermittent	Intermittent	Permanent
Duration of symptoms	Weeks-months	Weeks	Days-Weeks
Previous Surgery / Trauma	Traumatic iritis? Commotio?	Can be associated	Can be associated
Previous Ocular History	AMD? RVO?	Previous surgery	Previous surgery

If you do  
need to  
examine

...

Vision

PVD - tobacco dusting (Shaffer's sign), Weiss Ring

Retinal - tears, lattice degeneration, detachment

If no tears found and mass found - think of choroidal lesion

If RD looks smooth with overlying vessels - think of retinoschisis

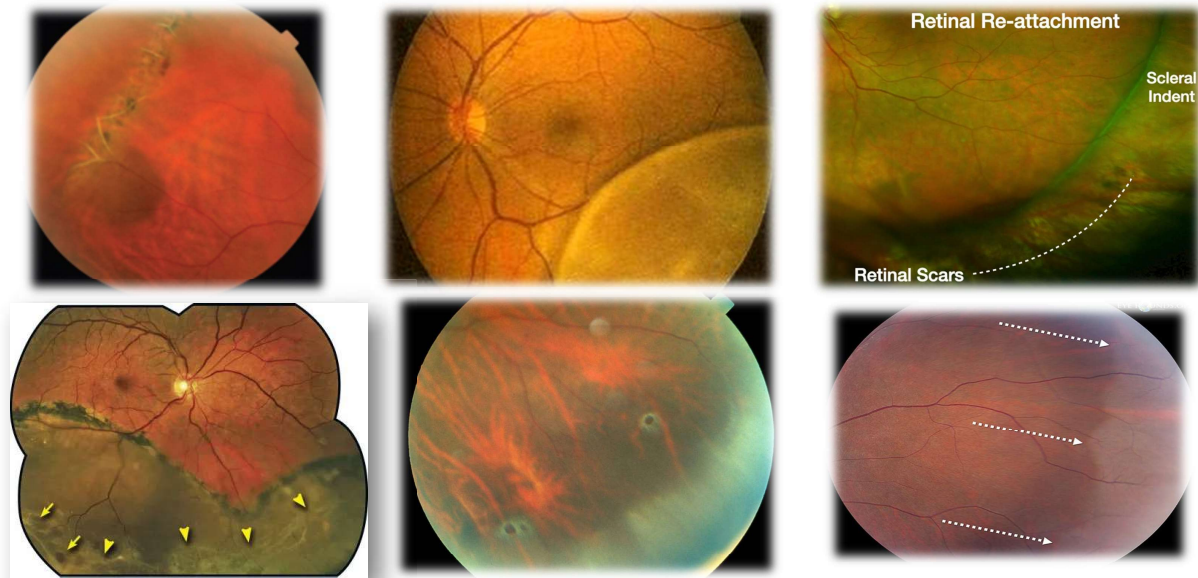
Don't forget the rest of ocular examination - anterior segment, IOP, optic nerve, retinal vessels, macula, visual fields

## Fundal findings & what to do?

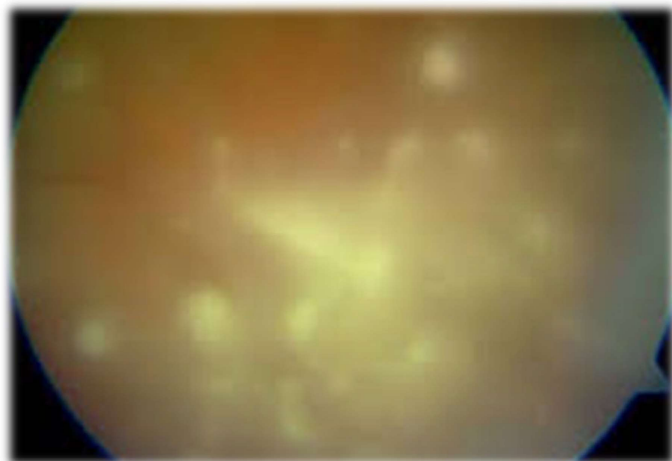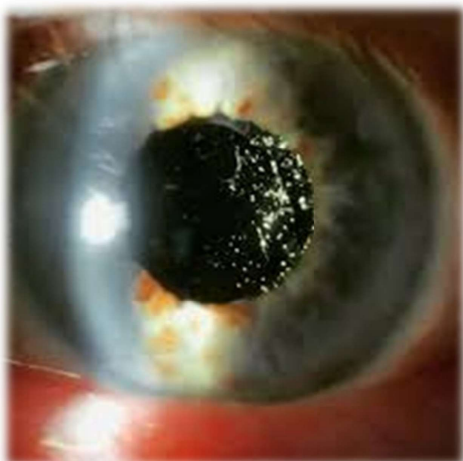Category	Routine	Semi-Urgent (2-4 weeks)	Urgent (1 day)
White without pressure / Flat atrophic holes	✓		
Lattice degeneration +/- holes (flat)	✓		
Holes > 1 DD - flat	✓	✓ - traction	
Ooperculated tears (flat)	✓ chronic	✓ - symptomatic	✓ - lifted tear
Retinal tears	✓ - complete pigmented		✓
Vitreous haemorrhage		✓ - known DR	✓
Retinal detachment		✓ - known DR	✓
Chronic retinal detachment	✓ - complete pigmented	✓ - incomplete pigment	✓ - acute on chronic

# Confusing findings

---



# More confusing findings...



# Summary



80-90% is due to the vitreous/retinal related pathology.



Good history helps determine urgency and examination confirms it.



If any doubts, seek another colleague opinion or call BMEC for doctor advice.



Your cooperation is very much appreciated and valued!



QIP in BMEC - improved telecommunication service - transfer of images



QIP in BMEC - feedback to optician/optom services - learning process